

Endoscopic hemorrhoidal ligation and sclerotherapy without anesthesia : Report of an initial experience

Toru Zuiki¹⁾²⁾, Masanobu Hyodo²⁾, Yasuo Kondo¹⁾²⁾,
Kunihiko Shimura¹⁾²⁾, Hideo Nagai²⁾

We introduced endoscopic hemorrhoidal ligation and sclerotherapy (EHLS) without anesthesia to relieve postoperative anal pain of conventional methods and to avoid adverse effects of anesthesia, shortening the postoperative hospital stay. We evaluated its effectiveness and usefulness compared with other surgical hemorrhoidal treatments under anesthesia, in terms of operative time, hospital stay, incidence of postoperative complications, and severity of anal pain. Postoperative satisfaction was also investigated using questionnaires. Twenty-one patients were treated with ligation-excision (7 cases), rubber band ligation (9 cases), and laser therapy (5 cases), which were all together designated as "other operations" group. Twenty-three patients underwent EHLS 27times. There were no significant differences in the backgrounds between EHLS and "other operations" groups. The operative time and hospital stay in EHLS were significantly shorter than those of "other operations". The incidence of postoperative complications including anesthetic sequelae was higher in the "other operations" group. Postoperative anal pain after EHLS was much slighter than after other operations. Patients in both groups were satisfied with their postoperative situation. In conclusion, EHLS without anesthesia seems to be a beneficial treatment for internal hemorrhoids in terms of low invasiveness and patients' satisfaction similar to the conventional surgery.

(Key words : Hemorrhoid · Anesthesia · Endoscopic hemorrhoidal ligation and sclerotherapy (EHLS))

I Introduction

Hemorrhoids are recognized as a benign perianal disorder and apt to be treated by conservative therapy. For the treatment of symptomatic hemorrhoids including anal bleeding and prolapse, surgical procedures such as ligation-excision, rubber band ligation, sclerotherapy, and laser therapy have been performed. Presence of various treatments for hemorrhoids means a variety of pathogenesis and a lack of a predominant therapy for this common disease. Because spinal or caudal anesthesia is indispensable for the surgical procedures to reduce the anal pain

1) Department of Surgery, Sashima Red-Cross Hospital, Ibaraki

2) Department of Surgery, Jichi Medical School Hospital, Tochigi, Japan

and to relax the perianal muscle tension, surgeons must be aware of not only perioperative but also postanesthetic adverse effects.

Until March 2004, we performed the above-mentioned surgical procedures : ligation-excision, rubber band ligation, and laser therapy under anesthesia. We then introduced endoscopic hemorrhoidal ligation and sclerotherapy (EHLS) without anesthesia to relieve the postoperative pain and the anesthetic side effects, and to shorten the postoperative hospital stay.

EHLS is a modification of endoscopic vascular ligation (EVL) for esophageal varices invented by Isshi et al. It has the advantage of being pain-free even without spinal or caudal anesthesia, being performed with simple preparation, and having the potential to be repeated on an outpatient basis¹⁾.

Herein, we retrospectively evaluated the effectiveness and usefulness of EHLS without anesthesia compared with other surgical hemorrhoidal treatments under anesthesia.

II Patients and methods

A Patients)

Between November 2000 and January 2005, 44 patients with symptomatic hemorrhoids underwent treatments in Sashima Red-Cross Hospital. Our hospital's indications for hemorrhoids are that patients complain of bleeding and prolapse in spite of conservative therapies, and that they agree with surgical treatments with informed consents.

Up to March 2004, 21 patients had been treated with ligation-excision (7), rubber band ligation (9), and laser therapy (5) under spinal, caudal or epidural anesthesia. All the patients were hospitalized after surgery.

Twenty-three patients underwent EHLS without anesthesia from April 2004 through January 2005. A total of 27 EHLSs were performed : once for 19 patients and twice for 4 patients. Eight EHLSs were followed by hospitalization due to coexistence of other diseases or at patients' request. Others were followed after EHLSs on an outpatient basis.

Only polapse hemorrhoids classified with Goligher grade 4 was contra-indicated for EHLS.

As for the backgrounds, we scored the preoperative severity of hemorrhoids using the Goligher classification ranging from grade 1 to 4. There were no significant differences between the EHLS group and the "other operations" group in the backgrounds (Table 1).

B Methods)

1 Surgical procedures for hemorrhoids under anesthesia

The following procedures were performed under spinal, caudal or epidural anesthesia.

1) Ligation-Excision (Milligan-Morgan method)

After setting Parks' bivalve speculum via the anus, 2 or 3 arteries feeding the hemorrhoids were ligated in advance, and then excised up to the arteries. The wounds were left open or semi-closed^{2,3)}.

2) Rubber band ligation

We identified hemorrhoids and ligated their feeding arteries via anoscopy, then ligated the hemorrhoids using a McGiveny type ligator with rubber bands^{4,5)}.

3) Laser therapy

Table 1 Patient backgrounds

| | EHLS without anesthesia | Other operations under anesthesia | |
|---|-------------------------|-----------------------------------|------|
| | | Ligation-excision | 7 |
| | | Rubber band ligation | 9 |
| | | Laser therapy | 5 |
| Number of procedures | 27 | 21 | |
| Patients | 23 | 21 | |
| Age | 65.4±11.6 | 60.9±10.7 | n.s. |
| Gender (Male/Female) | 16/11 | 13/8 | n.s. |
| Goligher's classification (grade1/2/3/4) | (8/13/5/1) | (4/8/7/2) | n.s. |

n.s. : not significant




Figure 1 Hemorrhoids are observed by endoscope equipped with EVL device. Arrow shows the dentate line of anal canal.

After injecting indocyanine green into the submucosal layer of each hemorrhoid, we coagulated the piles by laser beam (DIOMED25^R, Olympus, Tokyo, Japan)⁶⁾.

2 Endoscopic hemorrhoidal ligation and sclerotherapy (EHLS) without anesthesia

We applied a gastrointestinal endoscope (XQ200^R, Olympus, Tokyo, Japan) to EHLS, equipped with EVL device (PNEUMO-ACTIVATE EVL DEVICE^R, Sumitomo Bakelite, Tokyo, Japan). For sclerotherapy, we utilized an infusion device (DISPOSABLE INJECTOR NM^R, Olympus, Tokyo, Japan) and oily solution of polidocanol (AETHOXYSKLEROL^R, Sakai-Kaigen, Tokyo, Japan) or 5% phenol almond oil (PAOSCLE^R, Torii, Tokyo, Japan).

First, the rectum was prepared by 150 ml glycerin enema. We then inserted the endoscope into a laterally positioned patient in the same way as a colonoscopy, and turned it upside down around the rectal ampulla, then observed the location of the hemorrhoids, especially in relation to the dentate line of the anal canal (Figure 1). For ligation, we sucked the hemorrhoid sufficiently apart from the dentate line. If the patient complained of anal pain at this point, we

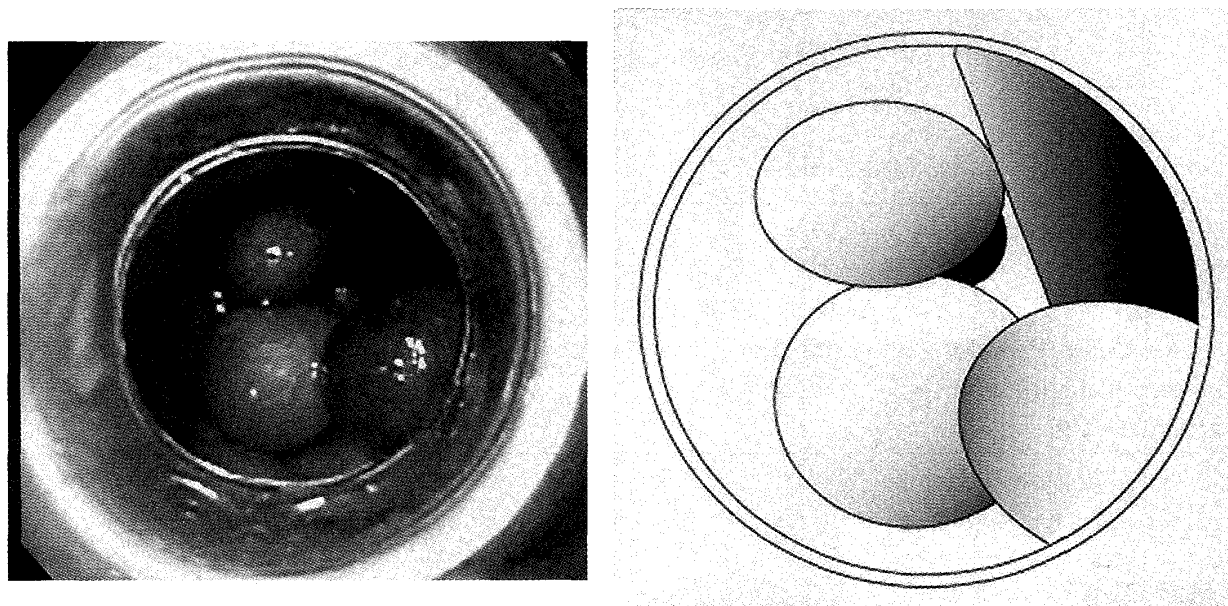


Figure 2 Several hemorrhoids are ligated by EVL device.




Figure 3 After ligation, sclerotherapy is being performed by injection device around the ligated points.

ceased sucking and re-sucked it from a little farther to the oral side of the hemorrhoid. Depending on the size and severity of piles, we performed 3 to 6 ligations (Figure 2) and added sclerotherapy around the ligated points (Figure 3).

C Investigated issues

We compared the postoperative results between EHLS and other operations retrospectively, in terms of the operative time, hospital stay, incidence of adverse complications including anesthesia-related ones, and severity of anal pain indicated by use of analgesias. Postoperative satisfaction more than one month after treatment was also investigated with questionnaires using interview, grading the scores of -1 (aggravated), 0 (no change), 1 (improved), and 2 (markedly improved).

Table 2 Postoperative results

| | EHLS without anesthesia | Other operations under anesthesia | |
|------------------------------|-------------------------|-----------------------------------|--------|
| Operative time(min) | 19.7±8.0 | 35.5±21.2 | p<0.05 |
| Hospital stay(day) | 3.2±4.0 | 9.5±4.9 | p<0.05 |
| Complications | | | |
| Total (including anesthesia) | 5/27 | 16/21 | p<0.05 |
| Anal pain | 2/27 | 10/21 | p<0.05 |
| Anesthetic sequelae | 0/27 | 7/21 | p<0.05 |
| Satisfaction | 0/3/12/12 | 0/1/9/10 | n.s. |
| (-1/0/1/2) | | | |

n.s. : not significant

Statistical analyses

Data on the age, operating time, and hospital stay were described as mean±standard deviation, and data on the gender, Goligher classification, complications, and satisfaction questionnaires were presented as ratios. To analyze the two groups (EHLS without anesthesia vs. other operations under anesthesia) statistically, Student's unpaired t-test was used for age, operative time, and hospital stay, Chi-square test was used for gender and complications, and Mann-Whitney U test for Goligher classification and patients' satisfaction. P<0.05 was considered significant.

III Results

The operative time (19.7±8.0min) and hospital stay (3.2±4.0days) in the EHLS group were significantly shorter than those in the "other operations" group. The incidence of postoperative complications including anesthetic sequelae such as dysuria, hypotension, and post-spinal headache was higher in the "other operations" group. Postoperative anal pain in EHLS was much slighter than that in other operations. Patients in both groups were satisfied with their postoperative situation without a significant difference. (Table 2).

IV Discussion

Based on the 5-year experience of hemorrhoidal therapy in Sashima Red-Cross Hospital, EHLS was superior to other hemorrhoidal therapies in terms of shorter operative time and hospital stay, and fewer postoperative complications and complaints of pain. Moreover, the questionnaire survey showed nearly the same satisfaction in patients as with other hemorrhoidal therapies.

It was reported by Fukuda et al that 89% of patients undergoing endoscopic hemorrhoidal ligation had been satisfied with their postoperative situation 1year after treatment, and that it was a simple and safe procedure⁷⁾. Su et al also described that it improved 95.4% of anal bleeding and 92% of prolapse⁸⁾. Endoscopic hemorrhoidal sclerotherapy was invented in 1928 by Morley et al.⁹⁾ and introduced to Japan in the 1970's. Endoscopic ligation combined with sclerotherapy, or EHLS was reported by Isshi et al, who described its effectiveness as 94%¹⁾.

EHLS enables us to observe hemorrhoids and the dentate line clearly by retroflexed view,

and to treat all areas of the anal canal and ligate the hemorrhoids by the EVL device smoothly. That is the reason why the operative time was shorter than the other operations even in our initial experience. Furthermore, it can avoid ligation on the dentate line, sparing patients postoperative anal pain¹⁰⁾. Since hemorrhoidal operations have been well-known painful procedures, EHLS seems to be a breakthrough therapy in this respect.

Other advantages of EHLS include no necessity for spinal or epidural anesthesia, and a simple preparation by an enema just before the procedure. Anesthesia is necessary for most other operations for hemorrhoids, which can induce postoperative anesthetic complications such as allergic reaction, hypotension, dysuria and post-spinal headache. These complications also require patients to be hospitalized for observation. Because EHLS needs no anesthesia or hospital admission, and has no possibility of complications associated with anesthesia, it is superior to other treatments in terms of less invasiveness and cost. The simple preparation not only eases the burden on patients but also reduces co-medical load. These advantages are particularly favorable for aged and feeble patients.

Another unique advantage of EHLS is repeatability. In our experience of 4 patients undergoing EHLS twice, all patients were satisfied with the second postoperative situation. Isshi et al reported that two sessions of the procedures increased the effectiveness of EHLS¹⁾.

As for the indications of EHLS, Isshi et al and Bekelhammer C et al.^{1,11)} recommended EHLS for all Goligher grades except Goligher 4. We then contra-indicated Goligher 4 for EHLS. Because EHLS is effective and useful for hemorrhoids within Goligher grade 3 and its favorable outcome seems to depend on the preoperative assessment, we must take care of the indication for EHLS according to the severity of hemorrhoids.

V Conclusions

From our initial experience, EHLS without anesthesia seems to be a useful treatment for internal hemorrhoids in terms of invasiveness and patients' satisfaction.

References

- 1) Isshi K, Yamamoto M, Takahashi N et al. : Combined fiberscopic ligation and sclerotherapy for internal hemorrhoids. *JMJ* 45 : 67-73, 1998.
- 2) Milligan ET, Morgan CN, Jones LE et al. : Surgical anatomy of the anal canal and the operative treatment of haemorrhoid. *Lancet* 2 : 1119-1124, 1937.
- 3) Ruiz-Moreno F : Hemorrhoidectomy-How I do it ; Semiclosed technique. *Dis Colon Rectum* 20 : 177-182, 1977.
- 4) Blaisdell PC : Office ligation of internal hemorrhoids. *Am J Surg* 96 : 401-404, 1958.
- 5) Barron J : Office ligation treatment of haemorrhoids. *Dis Colon Rectum* 6 : 109, 1963.
- 6) Usui Y : ICG dye enhanced laser therapy for hemorrhoids : a new procedure. *J Jpn Soci Coloproct* 54 : 921-925, 2001 (In Japanese).
- 7) Fukuda A, Kajiyama T, Arakawa H et al. : Retroflexed endoscopic multiple band ligation of symptomatic internal hemorrhoids. *Gastrointest Endosc.* 59 : 380-4, 2004.
- 8) Su MY, Chiu CT, Wu CS et al. : Endoscopic hemorrhoidal ligation of symptomatic internal

- hemorrhoids. *Gastrointest Endosc.* 58 : 871-4, 2003.
- 9) Morley AS : An improved technique for the treatment of internal hemorrhoids by injection. *Lancet* 1 : 543-545, 1928.
 - 10) Shioda Y, Onda M, Sakuma T et al. : Endoscopic hemorrhoidal ligation from the rectum. *J Nippon Med Sch* 69 : 451-455, 2002. (In Japanese).
 - 11) Berkelhammer C, Moosvi SB : Retroflexed endoscopic band ligation of bleeding internal hemorrhoids. *Gastrointest Endosc* 55 : 532-537, 2002.

内視鏡的痔核結紮硬化療法の有用性

瑞木 亨¹⁾²⁾ 俵藤 正信²⁾ 近藤 泰雄¹⁾²⁾
志村 国彦¹⁾²⁾ 永井 秀雄²⁾

要 訳

痔核手術の疼痛軽減・麻酔副作用の回避・在院日数短縮を目的に内視鏡的痔核結紮硬化療法 (EHLS) を導入した。今回その有効性について従来行なってきた外科的痔核治療と比較し検討した。検討項目は手術時間, 在院日数, 麻酔合併症を含めた術後合併症の頻度, 術後疼痛の程度, アンケートによる患者の満足度である。従来の外科的痔核治療は, 痔核結紮切離法 7 例・ゴム結紮法 9 例・レーザー治療 5 例でいずれも麻酔下で施行されており, この 21 例を“他治療”群とした。EHLS は 23 例に計 27 回施行されてい

た。EHLS 群と“他治療”群の患者背景に差は認めなかった。手術時間と在院日数は EHLS 群で有意に短かった。麻酔合併症を含めた術後合併症頻度は EHLS 群で有意に少なく, 術後疼痛の程度も EHLS 群で有意に軽度であった。アンケートによる患者の満足度調査では両群とも十分な満足度が得られていた。麻酔を必要としない内視鏡的痔核結紮硬化療法 (EHLS) は, 低侵襲でありコスト面でも優れ, また患者満足度も高く有用な外科的痔核治療であると考えられた。

1) 猿島赤十字病院外科

2) 自治医科大学消化器一般外科