

Original Article

A new portable, bedside apexcardiograph: Development of a prototype and initial clinical experience

Shigehiro Kuroki¹⁾, Kazuomi Kario²⁾, Eiji Kajii¹⁾

Abstract

Palpation of the apex beat of the heart has traditionally been an important part of the physical examination, although the information obtained is very subjective. To obtain objective information, apexcardiograms have been used. However, the conventional mechanocardiograph is a large device requiring a special sound-proof room with at least two examiners. Because of these disadvantages related to space and staffing, as well as the development of more convenient echocardiography, the mechanocardiograph has gradually fallen into disuse in spite of its value in providing part of an objective cardiac examination.

In this study we describe the development of a new apexcardiograph. This recorder is a small mobile device and can be easily used by a single examiner. Utilizing this new device, we recorded bedside visible and objective apexcardiograms. The contours of the apexcardiograms recorded by this device helped us to correctly identify and comprehend the pathophysiology of various heart diseases at the bedside. The innovative design of the portable apexcardiograph has the potential to improve cardiac examination and diagnosis, and contribute to clinical practice and medical education at the patient's bedside.

(Key words: palpation, apexcardiogram, clinical practice, medical education)

Introduction

The physical examination is a fundamental part of clinical practice. Cardiology practice, in particular, requires in-depth inspection, palpation and auscultation during the physical examination. This emphasis on a thorough physical examination led to the development of the apexcardiograph (mechanocardiograph), a device for visualizing the apex beat. The apexcardiograph, however, has recently fallen out of favor for several reasons. First, the conventional apexcardiograph is a large device that requires a special, sound-proof room, so it cannot be used at the bedside. Second, it can only be used with patients who are well enough to be transferred to such special rooms. Third, the device has both sensor and recorder components, so at least two examiners are required to operate the device. Fourth, the rapid development of echocardiography has made easy and fast diagnosis of heart disease possible.

While a thorough physical examination is still very important¹⁾, there is no way to objectively show the findings of palpation at the bedside. In addition, there is no examination to evaluate the complicated three-dimensional movement of the left ventricle²⁾. In order to resolve both of these issues, we focused

¹⁾ Division of Community and Family Medicine Center for Community Medicine Jichi Medical University

²⁾ Division of Cardiovascular Medicine Jichi Medical University School of Medicine

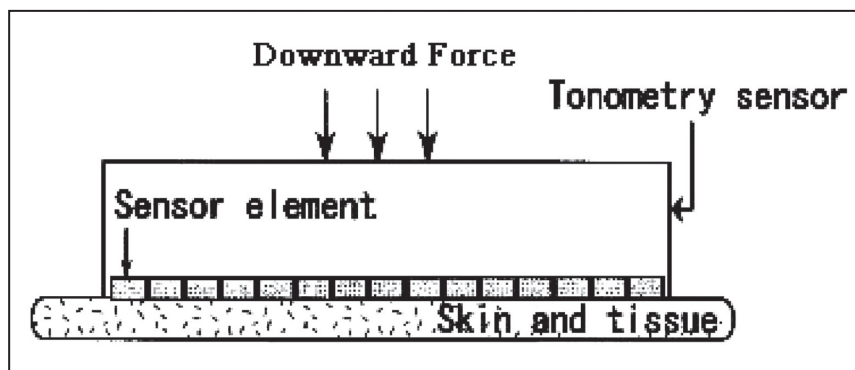


Figure 1 structure of the tonometry sensor

on the apex beats of the heart^{3) 4) 5)} and developed a small, portable bedside apexcardiograph, which potentially can replace the conventional, larger device. In this study, we compared the apexcardiogram recorded by the new device to that acquired by the conventional device.

Subjects and methods

Overview of the new apexcardiograph

The new device employs an analog signal output system from a pressure sensor and a data-logging system using a personal computer (PC). The device is 30 cm in width, 55 cm in depth, and 90 cm in height. The tonometric sensor for apex beats is a multi-purpose pressure sensor⁶⁾ used in a device for measuring arterial pulse wave velocity (Japan Colin, currently Omron Healthcare Co., Ltd., Tokyo, Japan). The sensor is 6-mm by 13-mm on which 15 strain gauges (as sub-sensors) are arranged as a linear array⁷⁾ (Figure 1). The sensing range of each sub-sensor is 0.20 mm × 0.67 mm. The 15 sub-sensors send direct-current voltage signals to the amplifier unit. Each of the 15 sub-sensors is divided on a time scale according to RR intervals detected in electrocardiographic signals from another sensor, and the output from the sub-sensor that produces apex beat signals with the maximum amplitude is sent to the PC as an analog signal.

After the analog signals are sampled and stored, the analog/digital (A/D) -converted digital data are processed arithmetically and are shown on the PC screen (Figure 2). The graphical data are printed. The dynamic ranges are 0 to 5 volts at the analog signal output and ± 5 volts at the PC. The sampling rate and anti-aliasing filtering are set at 1200 Hz and 300 Hz, respectively. On the PC screen, from the top to the bottom, the synchronized electrocardiac, phonocardiogram, and apex beat information from the sensors are shown in an electrocardiogram, a phonocardiogram, and an apexcardiogram, respectively. A horizontal axis is set as the time axis with 1200 points indicating one second.

Overview of the conventional apexcardiograph

A mechanocardiograph, MIC-9800 (Fukuda Denshi Co., Ltd., Tokyo, Japan), was used for comparison with the new device. The device is 60 cm in width, 80 cm in depth, and 180 cm in height. The sensor measures the alternating-current voltage signals and the average pressure per unit contact area using

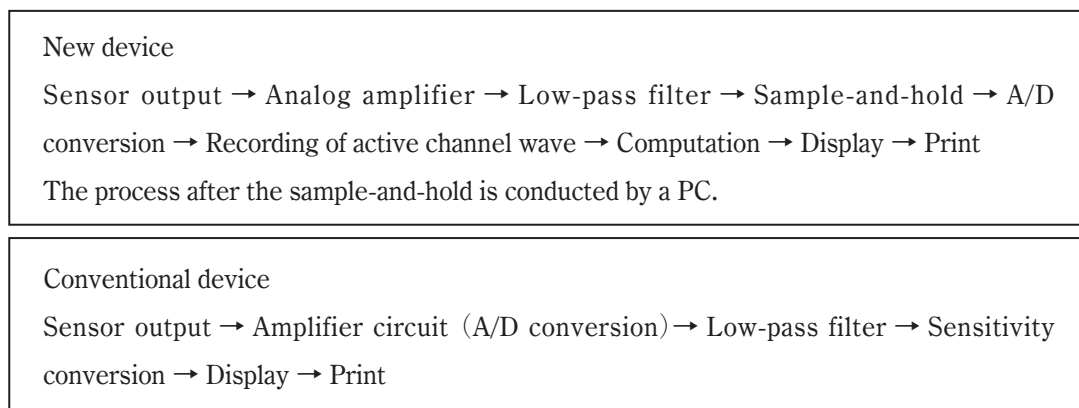


Figure 2 Comparison of the data circuit between the new device and the conventional device

strain gauges. The time constant is 2.0 seconds. The contact area of the sensor is round, and it is 20 mm in diameter.

Subjects

Group 1: Six patients were tested with the new device. Among the six patients, there was one case of hypertensive heart disease, two cases of ischemic heart disease, one case of mitral stenosis, one case of mitral regurgitation, and one case of mitral valve prolapse

Group 2: Thirty-one subjects (17 men and 14 women) without any abnormality detected on physical examination, chest X-ray, or electrocardiogram, were tested with the new device as “controls”. Their average age was 44 years with a standard deviation (SD) of 19 years.

Examination

Apexcardiography was conducted with the subjects in mid-exhalation in the left semi-lateral decubitus position. Each examination was completed within ten seconds, and was then repeated. The examiner placed the sensor at the maximum point of apex beats on the subject's left chest wall with one hand and, with the other hand, recorded the beats on the PC screen using a mouse-driven operation. The recording was set to stop automatically ten seconds after it started.

The subjects in group 1 were studied within seven days before or after apexcardiography, if the subjects were deemed to be in a clinically stable condition. Apexcardiography with the new device were performed in an outpatient clinic or in a ward by a single examiner, and those performed with the conventional device (MIC9800) were performed by two examiners in a sound-proof room. Concurrent recordings of heart sounds were conducted with the phonocardio-sensor usually placed at the left sternal border of the third intercostal space. Electrocardiograms were recorded concurrently with lead II.

Extracting apex beat data

A normal apexcardiogram is shown in Figure 3. Each apex beat was separated by the time scale based on each RR interval in the electrocardiogram. Among the beats, the one with the largest amplitude was selected, and this beat and three adjacent beats were extracted in order to obtain four consecutive beat

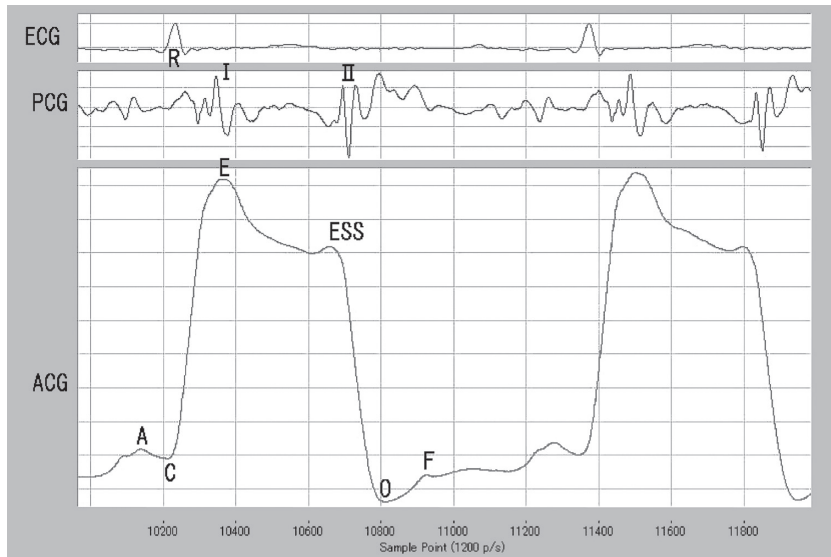


Figure 3 Apexcardiogram recorded with the new device for a 67-year-old, healthy female

R: QRS complex

I: mitral valve closure

II: aortic valve closure

A wave: contraction wave of the left atrium

C point: beginning of the left ventricular contraction

E point: beginning of the left ventricular ejection

ESS end systolic shoulder: beginning of relaxation of the left ventricle

O point: lowest point in the early diastolic phase

F wave: rapid filling wave of the left ventricle

waves. The beats were extracted so that the beat with the maximum amplitude was positioned at the second, third, or fourth position, allowing the A wave just before the C point to be measured. Except for the first wave, all of the waves were analyzed (Figure 4).

The apex beat of the heart is influenced by extra-cardiac factors, partially determined by the nature of the distance/relationship between the heart and the chest wall (partially determined by such factors as the general body size, shape of the chest, and location of the heart)⁸⁾. The location of the apex beat is also affected by respiration. Patients with diffuse left ventricular hypokinesis have weaker apex beats than those with normal left ventricular function. However, in cases of aortic regurgitation or mitral regurgitation with well-maintained left ventricular systolic function, stronger apex beats than normal can be observed. For patients in whom the systolic function has deteriorated, the apex beats become weaker. Even in subjects with normal hearts, the apex beats are weak if their chest walls are thick (due to increased muscle or fat, for example). Thus, it is impossible to compare quantitatively the strength of apex beats among subjects. Qualitative comparisons are conducted with adjustment for amplitude of the beats so that the entire range of the beat figures can be shown on the PC screen.

We used the C-E interval as an indicator to quantify the apexcardiograms recorded by the new device. In group 2, we evaluated the C-E intervals, which are the systolic upstroke times (SUT) of apexcardiograms that are attributable to the phase of isovolumetric contraction of the left ventricle (Figure 5). The C-E intervals were identified by utilizing the figures of the time-differentiated functions of the apexcardiograms⁹⁾. The C point was defined as the zero point at which the value of the derivation function goes

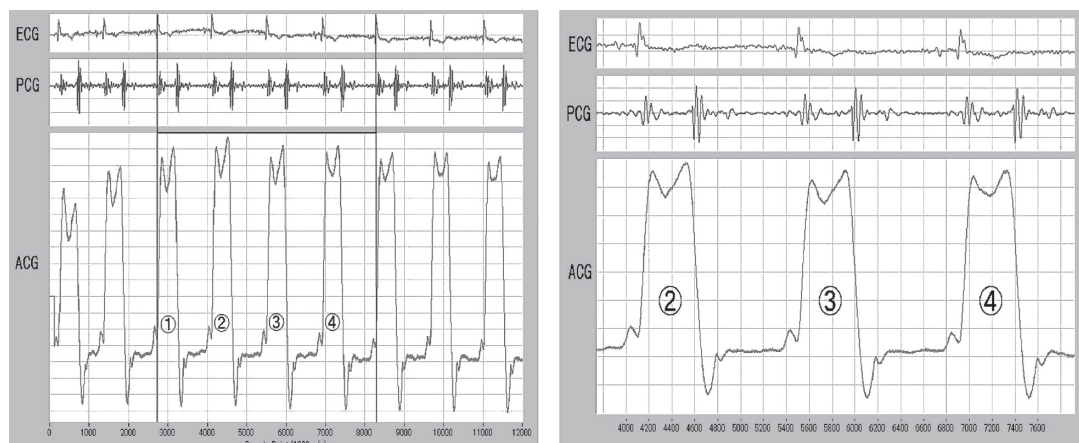


Figure 4 Extraction of beat waves

Wave ② is the wave with the maximum amplitude.

Three waves, including wave ②, were analyzed.

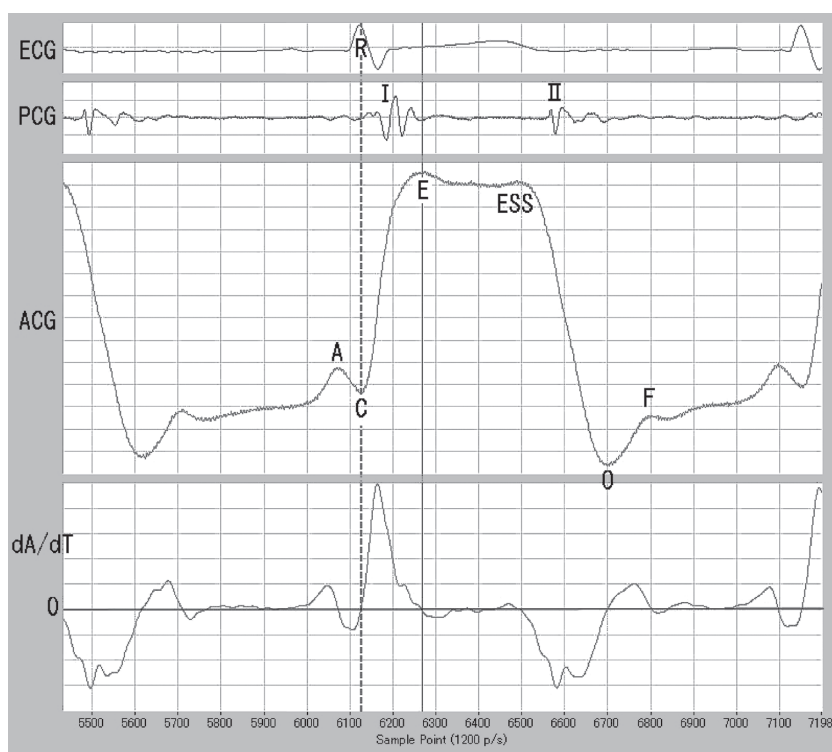

Figure 5 C-E interval

dA/dT : function wave of primary differentiated apexcardiogram

from negative to positive, and the E point was defined as another zero point at which the value of the function goes from positive to negative. The C-E interval is calculated as the average of measurements

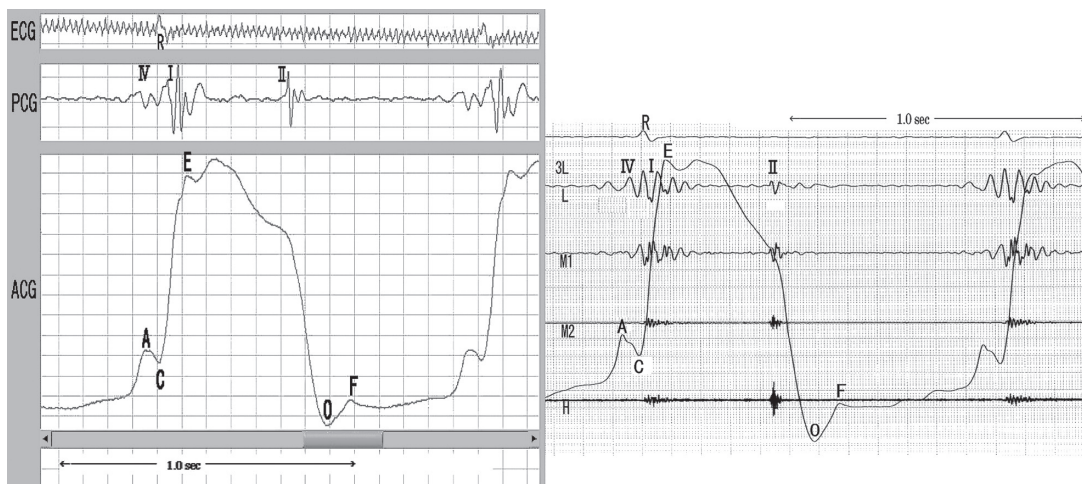


Figure 6-a Hypertensive heart disease

The left graph was recorded with the new device. Obviously, the A wave was observed, which corresponds to the IV sound. IV: sound of left atrial contraction

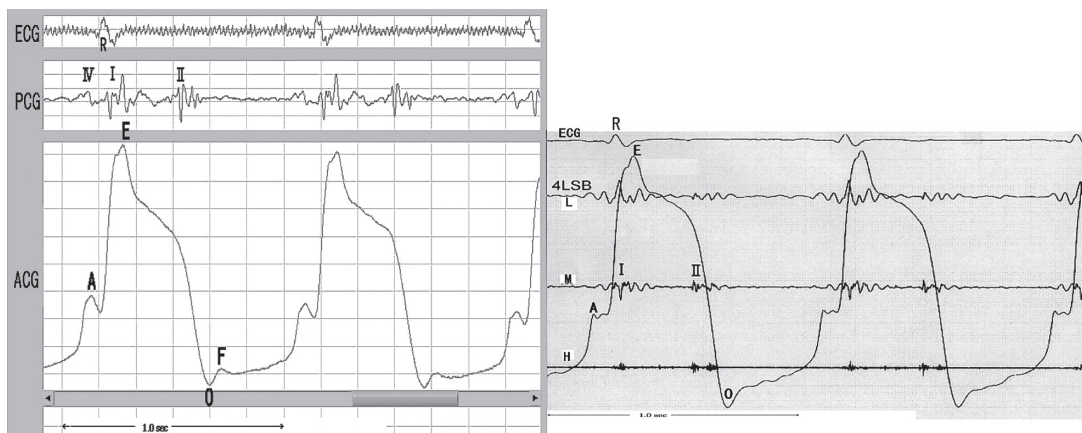


Figure 6-b Old myocardial infarction (antero-septum)

The left graph was recorded with the new device. A heightened A wave exists, but there is no ESS.

from the three extracted beats.

To evaluate reproducibility, inter- and intra-observer variabilities of obtained data were assessed. The C-E intervals were used for this purpose. The inter-observer variabilities were assessed between the C-E intervals obtained by the author and those obtained by the other examiners (all of whom were physicians). Before the tests, the author explained the purpose and method of the test to each examiner and provided practical instructions for several cases. All examiners except for the author, were unaccustomed to the new device that required the examiner to hold the sensor to the chest wall with one hand, operate the PC with the other hand, and simultaneously to judge whether the beat waves were valid and recorded. To facilitate the process for those unaccustomed to the technique, the examiners operated the

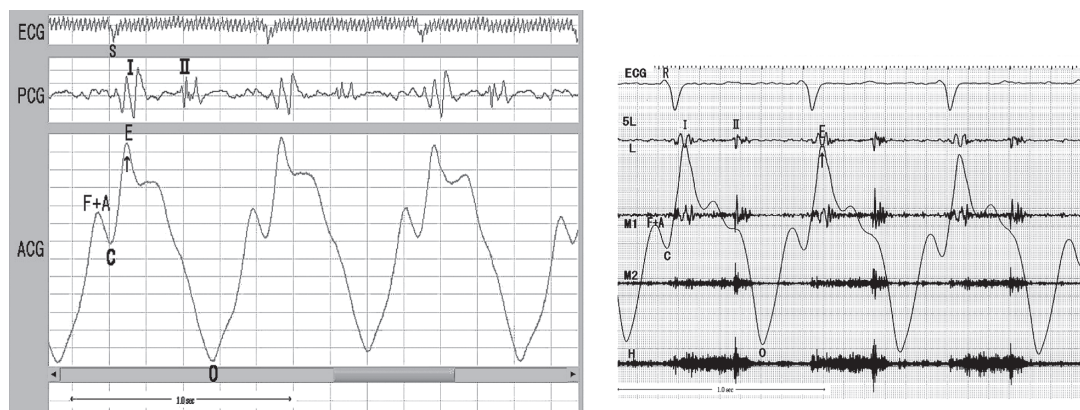


Figure 6-c Ischemic cardiomyopathy

The left graph was recorded with the new device. A sharp E wave (↑) and the merging of the F wave and A wave are observed.

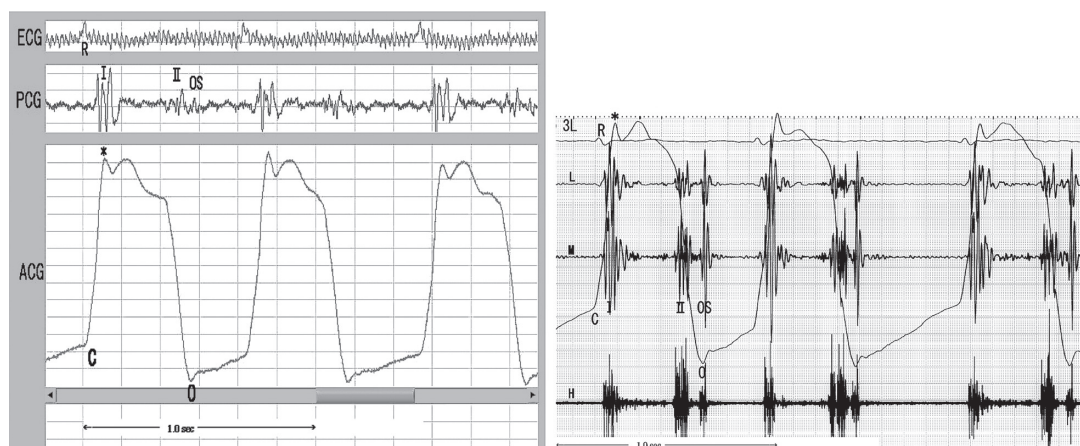


Figure 6-d Mitral stenosis with atrial fibrillation

The left graph was recorded with the new device. An impact wave (*) corresponding to the I sound, the O point corresponding to the opening snap (OS) of the mitral valve, and the slow uprising wave in the diastolic phase were observed.

sensors, and the author analyzed the beat waves and recorded them. The assessments of inter-observer variability were conducted under the above conditions. The data from 17 subjects, which were obtained by the author and each of the other six examiners, were assessed and compared. To assess intra-observer variability, tests were repeated by the author on the same subjects in a time interval that ranged between a day and a year (mean 120 days). Tests were repeated for 15 subjects to acquire the desired data.

Results

Apexcardiograms of patients with various cardiac diseases are shown in Figures 6a through 6f. For subjects in group 1, the new and the conventional devices were compared in terms of the amplitude of

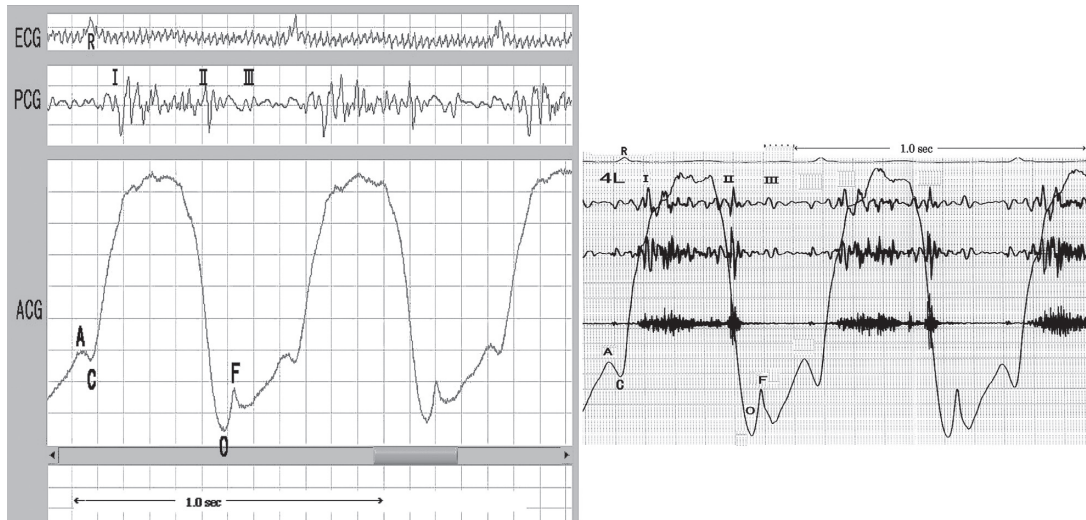


Figure 6-e Mitral regurgitation

The left graph was recorded with the new device. A sharp F wave corresponding to the III sound was observed. III: third heart sound

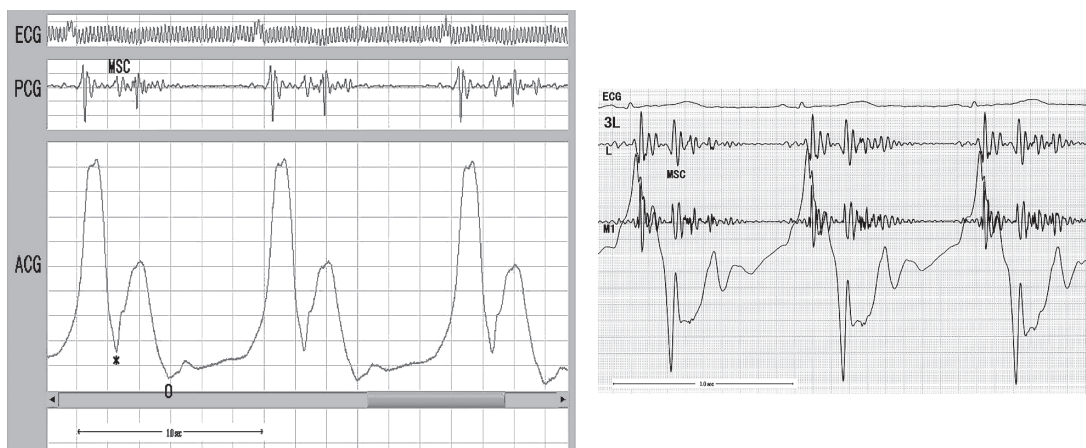


Figure 6-f Mitral valve prolapse

The left graph was recorded with the new device. A negative notch in the systolic phase corresponding to the mid-systolic click (MSC) was observed. In the record of the onventional device (right), the beat waves exceed the display range.

the apexcardiograms and the time phases of turning points A, E, ESS, O, and F. The amplitudes and time phases were similar for patients with hypertensive heart disease, ischemic heart disease, mitral stenosis, and mitral regurgitation. But the shape of the apexcardiograms using the new device for the patient with mitral valve prolapse was different from that using the conventional device, as shown in Figure 6f.

In group 2, the average C-E interval (SD) was 112 (15) milliseconds (Table 1). The inter- and intra-observer variability, based on measured C-E intervals, were analyzed. Correlation coefficients were 0.822

Table 1 C-E intervals of normal subjects

No	age	sex	HR	C-Interval (msec)	No	age	sex	HR	C-Interval (msec)
1	44	F	71	100	18	69	F	64	91
2	38	M	56	82	19	22	M	64	121
3	54	F	62	133	20	75	M	57	102
4	37	M	61	107	21	56	F	63	125
5	20	F	69	95	22	58	M	93	116
6	27	F	75	87	23	27	F	70	142
7	56	F	76	111	24	16	M	63	111
8	23	F	64	98	25	40	M	55	107
9	53	M	45	118	26	74	M	55	116
10	23	F	57	104	27	34	F	60	128
11	22	M	47	116	28	70	F	71	146
12	23	M	47	113	29	50	F	61	103
13	73	M	49	106	30	21	M	65	105
14	66	M	56	116	31	17	M	48	109
15	68	F	81	115	mean	44		63	112
16	51	M	63	116	SD	19		10	15
17	50	M	62	134					

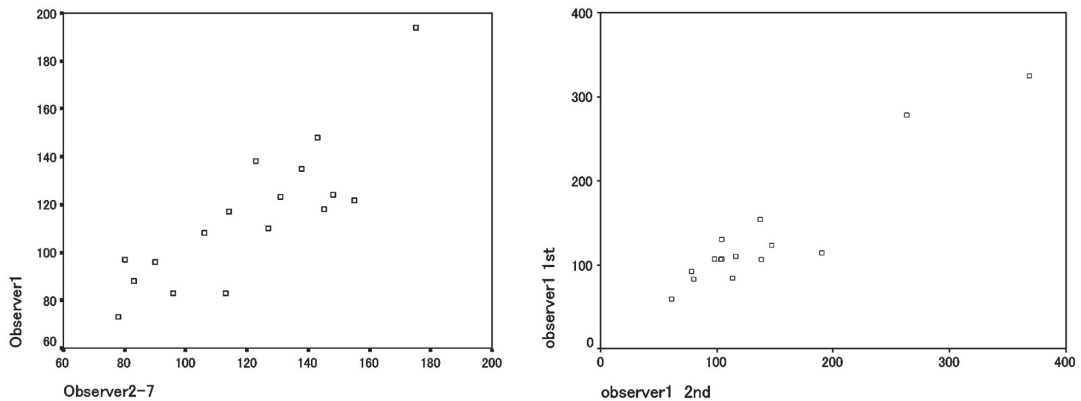


Figure 7 Inter-observer (left) and intra-observer (right) variabilities of C-E interval

and 0.780, respectively (Figure 7).

Discussion

The dynamics of the left ventricle is complicated (Figure 8)²⁾. Therefore, a single clinical test is not sufficient for accurate evaluation. Furthermore, the location of the heart changes according to the phase of both the cardiac and respiratory cycles. The apexcardiogram shows the temporal change of the pressure caused by the apex beat pushing against the chest wall and it is formed predominantly by the changes of left intra-ventricular pressure and volume.

The contour of the apexcardiogram also reflects the cyclic movement of the left ventricular apex when it comes close to the chest wall in the systolic phase and goes further away in the diastolic phase. Therefore, apexcardiography provides important information on the dynamics of the left ventricle¹⁰⁾. However,

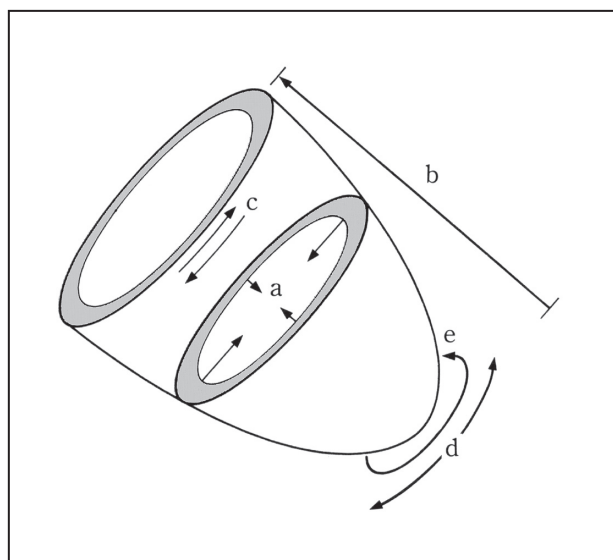


Figure 8 Dynamic of the ventricle

Ventricular movement toward the endocardial side (a)

Shortening of the distance between cardiac base and apex (b) Torsion (c)

Translocation of ventricle (d) Rotational movement (e)

(cited from Ishide 'Cardiodynamics and clinical practice,' 2nd edition, p.72)

evaluation of the apex beat has several methodological problems, and the effectiveness of apexcardiograms has always been controversial¹¹⁾.

The limitations of the conventional device have prevented wide clinical application of this potentially useful diagnostic test. Therefore, we developed a small, portable apexcardiograph and tested its effectiveness in this study. Due to differences in operational principles and differences in the range of measurement, the apexcardiograms recorded by the two devices were not identical, but the general shapes of the waves and their turning points were similar. The patient with mitral valve prolapse was thin, and that patient's intercostal spaces were markedly depressed so that the sensor of the conventional device could not be fitted. However, we were able to fit the sensor of the new device to the hollow intercostal spaces and obtain a clear wave of apex beats within which a systolic depression corresponding to the mid-systolic click sound could be observed. Further modifications of the shape and size of the sensor are needed for wider clinical applicability.

For quantitative assessment, we employed a time-phased analysis. The C-E intervals measured using the new device, for subjects with no abnormalities detected in the physical examination, chest X-ray, and electrocardiogram, were almost within the normal range of the C-E interval found with the conventional device. The average C-E interval was 112 ± 15 msec. Manolas et al have found that the SUT was correlated well with internal indices of ventricular function⁹⁾¹²⁾. The normal SUT ranged from 60 to 130 msec, whereas in patients with decreased myocardial function from any cause, this range was often exceeded. The SUT tended to decrease at increasing resting heart rate. However, the inverse correlation was very slight. For the inter-patient comparison of SUT, the influence of resting heart rate as a determinant of

contractile state per se has to be accounted for only when the heart rate differs greatly. Thus, the C-E intervals were not affected by heart rates.

The intra-observer reproducibility of the C-E interval measurement was found to be good in this study. Examiners of apexcardiography must be skillful in operating the device and reading the wave shape, because there are significant variations in the location, quality, and magnitude of the apex beat among different subjects. In spite of this, the inter-observer reproducibility of the measurement of the C-E interval was also confirmed to be good in this study.

The new device is smaller and lighter than the conventional device and, therefore, has the advantage of portability. The conventional device cannot be used for seriously ill patients who must remain in their beds in hospital wards. The new portable device is innovative in that a single examiner can take the device to a patient's location and perform the test directly at the bedside. The device can even be used for conducting tests in an outpatient setting. In addition, the new device can show better graphics with digital data.

It is conceivable that the new device substantially improves the quality of examination of the apex beat which is one of the essential components of cardiac physical examination. This is beneficial not only to cardiologists, but also to physicians-in-training and medical students. The device can be used in a setting where physicians explain cardiac conditions to patients. The device is thus expected to be useful in both clinical practice and medical education at bedside. For better performance of the device, the size and shape of the sensors should be improved, additional noise removal filters should be installed, and the method of measurement should be simplified. These improvements will enable further objectification and integration of bedside cardiovascular physical examinations which include not only examination of apex beat but also of other precordial pulsations, carotid arterial pulse, jugular venous pulse, abdominal aortic pulsation, and hepatic pulsation.

Acknowledgment

We acknowledge and are grateful for the contributions to this study provided by Mr. Toshihiko Ogura at Omron Healthcare Co., Ltd.

References

- 1) Fang JC and O'Gara PT : The History and Physical Examination: An Evidence-Based Approach BRAUNWALD'S HEART DISEASE SAUNDERS 2008, p147.
- 2) N Ishide : Ventricular Dynamics. Cardiovascular Dynamics and Clinical Practice 2nd edition Bunkodo 1992, p72
- 3) Chatterjee K : Examination of the precordial pulsation
http://www.utdol.com/utd/content/topic.do?topicKey=cardeval/5886&selectedTitle=3~150&source=search_result UpToDate August 2007
- 4) Deliyannis AA, Gillam PMS, Mounsey JPD et al.: The cardiac impulse and the motion of the heart. Heart 26: 396-411, 1964.
- 5) Sutton GC, Prewitt TA and Craige E : Relationship between quantitated precordial movement and left ventricular function. Circulation 41: 179-190, 1970.
- 6) Sato T, Nishinaga M, Kawamoto A et al : Accuracy of a Continuous Blood Pressure Monitor Based

- on Arterial Tonometry. *Hypertension* 21: 866-874, 1993.
- 7) Narimatsu K, Takatani S, Ohmori K et al.: A multi-element carotid tonometry sensor for non-invasive measurement of pulse wave velocity. *Frontiers Med Biol Engng* 11: 45-58, 2001.
 - 8) Fukuda N : Apical impulse or apex beat. *Inspection, palpation and auscultation of heart diseases Igakushoin* 2002, pp71-72.
 - 9) Manolas J, Wirz P, Rutishauser W : Relationship between duration of systolic upstroke of apexcardiogram and internal indexes of myocardial function in man. *Am Heart J* 91: 726-734 1976
 - 10) Abrams J : Precordial palpation. *Let Your Fingers Do the Walking. Classic teachings in clinical cardiology* Laennec Publishing 1996, pp85-89.
 - 11) Sakamoto T : Is So-Called "Apex" Really Apex? *Clinical Note A Story of Cardiac Apex J Cardiol* 25: 51-53, 1995.
 - 12) Tavel ME : *The Apexcardiogram: Its Clinical Application Clinical Phonocardiography and External Pulse Recording* 4th edition YEAR BOOK MEDICAL PUBLISHERS, INC. CHICAGO 1985 p246

新規のベッドサイド用小型心尖拍動測定器： 試作品開発とその臨床経験

黒木茂広¹⁾，荻尾七臣²⁾，梶井英治¹⁾

要 約

循環器系診察において心尖拍動は従来から大変重視されてきた。その客観的な記録として心尖拍動図がある。しかし、心尖拍動測定器が大型であるのみならず、測定環境は防音室のような制限された測定室で、測定者を最低2名要し、被検者も測定室に移動出来る者に限られていた。そのため、真にデータをとるべき重症患者の診察に活用されず、心エコーの発展もあって、医療現場では活用されていないのが現状で

あった。我々は1名だけで測定できる可搬型の新規心尖拍動測定器を開発し、ベッドサイドでの心尖拍動図を記録した。その結果、旧来の大型測定器と同等以上の心尖拍動所見を得ることが出来、その波形の特徴から左室の異常をベッドサイドで直ちに推測することが出来た。また、心尖拍動図を容易に記録できたことは、現場の診療と臨床医学教育に貢献できるものと思われた。

1) 自治医科大学 地域医療学センター・地域医療学部門

2) 自治医科大学医学部 循環器内科学部門