

**Case Report**

# Pneumatosis intestinalis in a patient with neutropenia following chemotherapy

Nao Kakizawa, Jun-ichi Sasaki, Yutaka J Kawamura, Fumio Konishi

## Abstract

Pneumatosis intestinalis (PI) are relatively rare conditions. Most cases are benign, but some with portal venous gas or intestinal infarction are severe. The pathogenesis is multifunctional, and optimal treatment depends on the cause. We report a case of chemotherapy-induced pneumoretroperitoneum in a 61 year-old female with small cell carcinoma. She had acute abdominal pain and came to the emergency room. She was diagnosed with pneumoretroperitoneum by using plain CT and underwent an operation. Laparotomy didn't reveal intestinal perforation and PI was considered to be the cause of her symptoms. Her postoperative course was uneventful with immediate improvement of her symptoms and discharged on 7<sup>th</sup> postoperative day.

(Key words: pneumoretroperitoneum, pneumatosis intestinalis, chemotherapy-induced, neutropenia, surgical treatment)

## Introduction

Pneumatosis intestinalis (PI) is a rare intestinal disorder, and often presents without an apparent bowel perforation. PI is characterized as a subserosal or submucosal gas-filled condition in the intestine, and known to occur in a variety of diseases. Typical symptoms are hematochezia, abdominal pain, vomiting, abdominal distention and diarrhea<sup>1)2)</sup>. Treatment for PI is basically conservative and some reports demonstrated surgical treatment<sup>3)4)</sup>.

We report a patient who underwent surgery for an acute abdomen with pneumoretroperitoneum in an immunosuppressed condition following chemotherapy.

## Case report

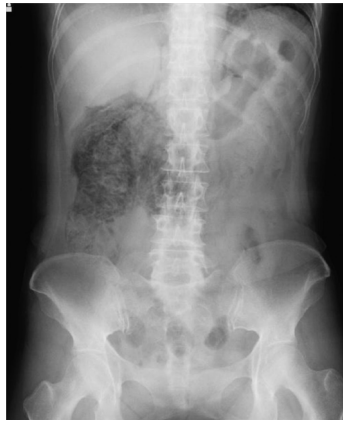A 61 year-old female was admitted to the emergency room with acute right side abdominal pain. There were no other digestive symptoms such as nausea, vomiting, diarrhea or constipation. She was afebrile, and her pain was spontaneous and severe. Physical examination showed severe tenderness extensively in the right abdomen.

She had past medical history of small cell carcinoma. Two months before admission she had brain tumor and underwent tumor resection. The pathological specimen revealed small cell carcinoma, but its primary proved to be unknown. She had started chemotherapy with carboplatin (CBDCA) and irinotecan

(CPT-11), and radiotherapy for brain metastasis on the previous month. She received the last chemotherapy on 11 days before the abdominal symptom.

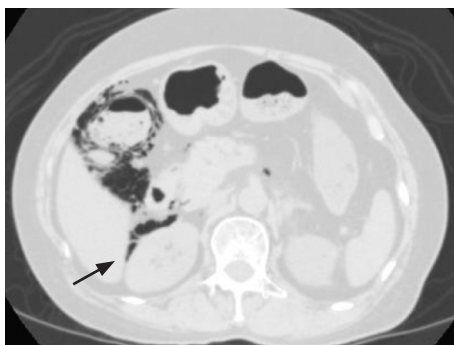
Laboratory data on admission revealed decrease in white blood cell and neutrophil count to  $1240 / \mu\text{l}$  and  $372 / \mu\text{l}$  respectively, with slightly elevated CRP level (to 1.57 mg/dl). And she had slight anemia (Hb 11.0 g/dl, Ht 31.2 %), but no thrombopenia. Blood gas analysis showed elevated lactic acid 18.5, and metabolic acidosis with respiratory compensation (pH 7.410,  $\text{PCO}_2$  32.0 Torr,  $\text{PO}_2$  57.8 Torr,  $\text{HCO}_3$  19.8 mEq/L, BE -4.1). Her liver and renal function data, and electrolytes are almost normal (AST 16 IU/L, ALT 23 IU/L, BUN 15 mg/dl, Cre 0.55 mg/dl, Na 139 mEq/L, K 3.5 mEq/L, Cl 109 mEq/L).

Abdominal X ray (Fig.1) presented a radiolucent area around the right intestine. Abdominal plain CT (Fig.2, 3, 4) showed abnormal air density around the right colon, duodenum, right kidney, and liver. She was diagnosed with subserosal emphysema and retroperitoneal emphysema. Intra-peritoneal free air or ascites were not identified.

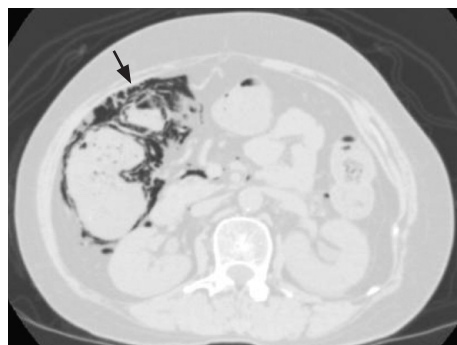


**Fig.1**

Abdominal X ray demonstrates hyperlucent shadow along the left side of the colon.



**Fig.2**



**Fig.3**

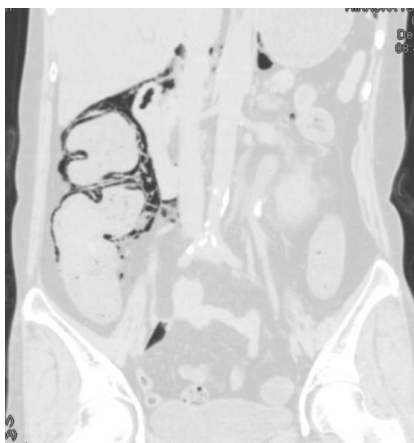


Fig.4

Abdominal plain CT scans show air density around ascending colon, duodenum, right kidney, and liver. The air seems to be in mesentery and retroperitoneum. She was diagnosed with subserosal emphysema.

Colonic perforation to the mesentery and retroperitoneum was strongly suspected. Her abdominal pain got heavier under observation in emergency room. We decided emergency operation. We started granulocyte colony-stimulating factor (G-CSF) and antibiotics.

Laparotomy revealed subserosal emphysematous change in the right colon and its mesentery, and pneumoretroperitoneum around the duodenum and the inferior vena cava. There was no finding of leakage of intestinal contents. We considered that such emphysematous change without intestinal perforation would be associated with the pathogenesis of PI. Operation was completed with opening the emphysematous retroperitoneal space and indwelling retroperitoneal drain catheterization.

Her severe abdominal pain was immediately improved after the surgery. Blood test on the 3<sup>rd</sup> postoperative day demonstrated improvement in white blood cell and neutrophil count to 3830/ $\mu$ l and 1991/ $\mu$ l, respectively, and G-CSF and antibiotics for the prevention of perioperative infection were finished on that day. Follow-up CT on the 6<sup>th</sup> postoperative day didn't show subserosal emphysema or pneumoretroperitoneum. She started normal diet on 3<sup>rd</sup> day and discharged on 7<sup>th</sup> postoperative day in good condition.

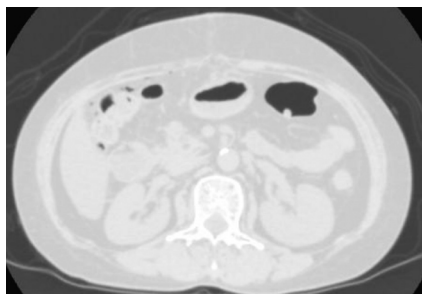


Fig.5

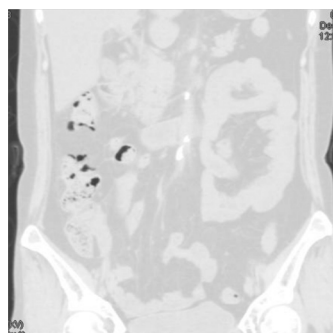


Fig.6

Abdominal plain CT scans on the 6th day of post operation showed small free air due to changes of post operation, and there was no sign of subserosal emphysema.

## Discussion

This case had pneumoretroperitoneum and subserosal emphysema. These findings generally indicate intestinal perforation. However, PI patient often presents such findings without intestinal perforation. PI is rare condition and it is characterized by the presence of multiple gas-filled cysts within the wall of some part of the gastrointestinal tract. Most PI cases have benign course, although some fulminant PI with necrotizing enterocolitis have a poor outcome.

It has been reported that 15% of PI is idiopathic and 85% is secondarily caused by various conditions. These are intestinal ischemia or infarction, inflammatory bowel diseases, infections and endoscopic procedures<sup>5) 6)</sup>, Alpha-Glucosidase inhibitor, and trichloroethylene<sup>19)</sup>. And some chemotherapeutic agents were reported to induce PI, which are cyclophosphamide, cytarabine, docetaxel, irinotecan, cisplatin, fluorouracil, and bleomycin<sup>3) 9) 10) 11) 12) 13) 14)</sup>. This patient also received irinotecan. PI with irinotecan is only one case reported previously<sup>9)</sup>.

The pathogenesis of PI is still unclear. There are some hypotheses to explain the mechanism of formation of cysts in PI, including (1) mechanical<sup>15)</sup>, (2) bacterial<sup>16)</sup> and (3) biochemical<sup>17)</sup> theories. Mucosal injury is important in (1) and (3). Ischemia, enteritis, radiation, or immunosuppression<sup>5)</sup>, and chemotherapeutic agents, which have a relation to mucosal injury, are thought to induce PI. The development of PI in this case may be attributed to chemotherapeutic agent. We thought that the causes of PI in this case were intraluminal high pressure which increased due to gas-producing bacteria, and mucosal injury which was caused by irinotecan<sup>18) 19)</sup>. The bacteria might easily grow in immunosuppressive state.

Previously-recommended conservative treatments for PI are oxygen inhalation, hyperbaric oxygen, antibiotics, and elemental diet. There are some case reports with successful non-operative treatment, and the duration of therapy is one or two weeks in most cases.

According to a recent article, by Goldberg et al, surgery was recommended when the patient had the likelihood of bowel ischemia or infarction; acute abdomen, metabolic acidosis, elevated lactic acid, elevated amylase, or portal venous gas, or remain symptoms after conservative measures<sup>3) 4) 8) 9)</sup>. Alexander et al reported that age  $\geq 60$  years, WBC  $> 12000/\mu\text{l}$ , sepsis, and vomiting are the significant factors to be treated and to select operations<sup>8)</sup>. In this case, abdominal pain was severe and her blood test data was abnormal. Worrying about the possibility of bowel perforation which must be high risk for sepsis in the immunosuppressive patient with neutropenia, we thought emergency laparotomy should be done.

The patient recovered for short period after the operation. The laparotomy showed no bowel perforation and also there was a possibility that administration of oxygen on perioperative period and exposure of abdominal cavity to the air by operation led to inhibit gas-producing bacteria proliferation, and early discharge.

## Conclusion

We experienced a case of irinotecan-induced pneumoretroperitoneum. Although rare, such an emergency condition as pneumoretroperitoneum should be kept in mind as one of the complications during chemotherapeutic treatment for cancer patients.

- 1) Knechtle SJ, Davidoff AM, Rice RP. Pneumatosis intestinalis. Surgical management and clinical outcome. *Ann Surg* 212: 160-165, 1990.

- 2) **Jamart, J.** Pneumatosis cystoids intestinalis. A statistical study of 919 cases. *Acta Hepatogastroenterol (Stuttg)* 26: 419-22, 1979.
- 3) **A. F. Kopp, E. Groenewaeler, M. Laniado** Pneumatosis cystoides intestinalis with pneumoperitoneum and pneumoretroperitoneum following chemotherapy. *Abdominal Imaging* 22: 395-397, 1997.
- 4) **Masataka Saito, Akiko Tanikawa, Katsuki Nakasute, et al.** Additive contribution of multiple factors in the development of pneumatosis intestinalis: a case report and review of the literature. *Clinical rheumatology* 26: 601-603, 2007.
- 5) **A Schulenburg, C Herold, E Eisenhuber, et al.** Pneumatosis cystoides intestinalis with pneumoperitoneum and pneumoretroperitoneum in a patient with extensive chronic graft-versus-host disease. *Bone Marrow Transplantation* 24: 331-333, 1999.
- 6) **R.Grassi, A.Pinto, G.Rossi.** Isolated Pneumoretroperitoneum Secondary to Acute Bowel Infarction. *Clinical Radiology* 97: 321-323, 1999.
- 7) 吉澤 寿 : トリクロロエチレンばく露歴を有し高圧酸素療法が奏効した腸管気腫性嚢胞症の1例 . 日本保健科学学会誌 2005, pp111-114.
- 8) **Alexander J G, Scott Q N, Ana B, et al.** Pneumatosis intestinalis in Adults: Management, Surgical indications, and Risk Factors for Mortality. *J Gastrointest Surg* 11: 1268-1274, 2007.
- 9) **David Kung, Daniel T Ruan, Rodney K. Chan, et al.** Pneumatosis intestinalis and Portal Venous Gas without Bowel Ischemia in a Patient Treated with Irinotecan and Cisplatin. *Dig Dis Sci* 53: 217-219, 2008.
- 10) **Galm O, Fabry U, Adam G, Oseka R.** Pneumatosis intestinalis following cytotoxic or immunosuppressive treatment. *Digestion* 64: 128-132, 2001.
- 11) **Hashimoto S, Saitoh H, Wada K, et al.** Pneumatosis cystoides intestinalis after chemotherapy for hematological malignancies: *Intern Med* 34: 212-215, 1995.
- 12) **Candelaria M, Bournon-Cuellar R, Zubieta JL, et al.** Gastrointestinal pneumatosis after docetaxel chemotherapy. *J Clin Gastroenterol* 34: 444-445, 2002.
- 13) **Shih IL, Lu YS, Wang HP, et al.** Pneumatosis coli after etoposide chemotherapy for breast cancer. *J Clin Oncol* 25: 1623-1625, 2007.
- 14) **Kenji M, Takatsugu O, Atsushi K, et al.** Pneumatosis cystoides intestinalis after fluorouracil chemotherapy for rectal cancer. *World J Gastroenterol* 14: 3273-3275, 2008.
- 15) **Pieterse, AS, Leong, AS, Rowland,R.** The mucosal changes and pathogenesis of pneumatosis cystoides intestinalis. *Human Pathology* 16: 683-8, 1985.
- 16) **Yale CE, Balish E, Wu JP.** The bacterial etiology of pneumatosis cystoides intestinalis. *Archives of Surgery* 109: 89-94, 1974.
- 17) **Sartor RB, Murphy ME, Rydzak E.** Miscellaneous inflammatory and structural disorders of the colon. *Textbook of Gastroenterology*, third edition, Lippincott Williams&wilkins, Philadelphia 1999, pp1877.
- 18) **Engelbert S, Thomas M.** Surgical aspects of pneumatosis cystoides intestinalis: two case reports. *Cases Journal* 2: 6452, 2009.
- 19) **Shindelman LE, Geller SA, Wisch N, et al.** Pneumatosis cystoides intestinalis: a complication of systemic chemotherapy. *Am J Gastroenterol* 75: 270-274, 1981.

# 化学療法中の好中球減少期に生じた腸間膜気腫症の一例

柿澤 奈緒, 佐々木純一, 河村 裕, 小西 文雄

## 要 約

腸間膜気腫症は、粘膜下や漿膜下に気腫が生じる病態で、その成因は明確にはなっていない。多くは腸管虚血、炎症性腸疾患などから、二次的に生じるとされている。治療法もいくつかあり、酸素持続投与や高圧酸素療法、抗菌薬、成分栄養を継続することによって保存的に治療したとの報告もあるが、乳酸アシドーシス

や敗血症を呈している場合には、腸管壊死の可能性が高く、致命的になるため、手術が推奨されている。われわれは、小細胞癌に対する化学療法中の好中球減少期に生じた腸間膜気腫症に対し、外科手術を施行し早期退院可能であった症例を経験したので、報告する。