

Case Report

Adult onset of C1q nephropathy manifesting only as microhematuria

Taro Sugase, Osamu Saito, Takako Saito, Tetsu Akimoto, Makoto Inoue, Yasuhiro Ando, Fumi Takemoto, Eiji Kusano

Abstract

We report a case of C1q nephropathy that manifested only as microhematuria in a 27-year-old man. The patient had presented with microhematuria for five years. A light microscopic study of a renal biopsy specimen showed predominant mesangial C1q deposition. Staining for C3 was positive in the same mesangial area. Stainings for IgA, IgG and IgM were slightly positive, however, these stainings were not on mesangial lesion, suggesting as non-specific pattern. Electron microscopy indicated high electron-dense deposits in the mesangial area. Histopathological studies were compatible with C1q nephropathy. In addition, laboratory data showed no serological evidence of collagen disease.

Usually proteinuria, occasionally nephrotic syndrome were reported in C1q nephropathy and C1q nephropathy often cause severe damage in the glomerulocapillary area from an early stage. From April 1994 to the end of 2010, we experienced 6 patients with possibility of C1q nephropathy among the all 3614 patients in whom renal biopsy was studied, and the prevalence of C1q nephropathy was 0.17%. All of 6 patients showed continuous microhematuria and proteinuria, and 2 of 6 cases had nephrotic syndrome. Current patient showed only hematuria without proteinuria. Hematuria alone is not a major manifestation of C1q nephropathy. Thus, the clinical findings in our patient may represent a rare phenotype of C1q nephropathy. We report the details of the case with a comparison with previous C1q cases.

(Key words: C1q nephropathy, hematuria, mesangial proliferative glomerulonephritis)

Introduction

C1q nephropathy is a criterion for a disease first reported by Jennette and Hipp in 1985^{1,2}. The entity is characterized by immune complex glomerulonephritis and complement deposits, most notably C1q, and by the absence of clinical and laboratory evidence of systemic lupus erythematosus (SLE). In light microscopy studies, several morphological patterns have been described for the disease, ranging from no histological glomerular alterations to focal and diffuse mesangial proliferative changes³. C1q nephropathy commonly presents with nephrotic-range proteinuria in older children and young adults and has a poor response to steroids.

Here, we report the case of a 27-year-old man with C1q nephropathy that manifested only as microhematuria. He had no symptoms and findings related to SLE or other collagen diseases. We compare the features of our patient with those of previously reported cases of C1q nephropathy.

Case report

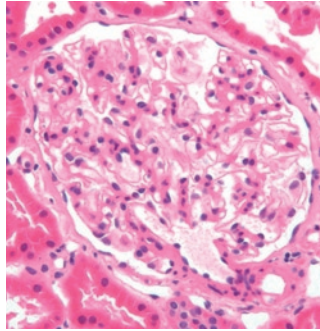
A 27-year-old man was referred to Utsunomiya Social Insurance Hospital in January 2008 due to detection of microhematuria. He had no pertinent family history and no previous illness. He was an office worker and had undergone an occupational medical check-up every year from 22 years old. At 22 years old, urinalysis was \pm for occult blood in a urinary dipstick examination. At 25 years old, urinalysis first showed 2+ for occult blood in the same examination. At 26 years old, urinalysis showed 1+ for protein (80mg/g.Cr) and 3+ for occult blood. He was planning to live abroad for 3 years due to work and this required a further examination, for which he was referred to our hospital.

Physical findings at hospitalization were height 165 cm and body weight 63 kg, with a body mass index of 22.9. Blood pressure was 118/58 mmHg and pulse rate was 65/min with regular rhythm. There were no abnormal physical findings. Laboratory findings showed a white blood cell count of 6600/ μ l; red blood cells, 489 x 10⁴/ μ l; hemoglobin, 14.8 g/dl; hematocrit, 43.0 %; and platelets, 31.5 x 10⁴/ μ l. Blood urea nitrogen was 13.6 mg/dl; serum creatinine, 0.82 mg/dl; uric acid, 7.2 mg/dl; total protein, 7.8 g/dl; albumin, 4.9 g/dl; C-reactive protein, 0.03 mg/dl; total cholesterol, 236 mg/dl; and triglyceride, 120 mg/dl. Urinalysis showed 2+ for occult blood and 1+ for protein (60mg/g.Cr). Total urinary protein excretion was 0.08g/day. Microscopic evaluation of urine demonstrated 30 to 49 red blood cells per high-power field (HPF) and no significant casts per low-power field (LPF). **Creatinine clearance was normal (119 ml/min). Serum immunoglobulin (Ig) G was 1163 mg/dl, IgA was 227 mg/dl, and IgM was 87 mg/dl. C3 was 129 mg/dl (normal range, 60 to 116 mg/dl), C4 was 30 mg/dl (normal range, 12 to 32 mg/dl), and CH50 was 40.6 U/ml (normal range, 34 to 49 U/ml). Antinuclear antibody and anti-DNA antibody were both negative, rheumatoid factor and LE tests were negative, and immunological tests showed no abnormalities.**

Percutaneous ultrasonography-guided renal biopsy was performed on Day 3 after admission. Eight glomeruli were identified in sections submitted for light microscopy examination. The specimens showed neither global sclerosis nor focal segmental lesions. There was trivial mesangial proliferation. There was no tubular damage or arteriolar change in the tubulointerstitial area. (Fig.1,2). Immunofluorescence showed dominant positive staining (3+) **of C1q in the glomerular mesangium (Fig. 3). In addition, staining for C3 was positive in the same mesangial area.** Stainings for IgA, IgG and IgM were slightly positive, however, these stainings were not on mesangial lesion, suggesting as non-specific pattern (Fig. 4). By electron microscopic survey, electron-dense deposits were present in the mesangial area (Fig. 5). Collectively, these results showed dominant C1q deposition in the mesangial area and had the appearance of mesangial proliferative glomerulonephritis without significant deposition of immunoglobulins. His laboratory data also showed no serological or clinical finding of SLE or other collagen disease. These results led to a diagnosis of C1q nephropathy.

Figure 1. Light microscopic findings. (HE staining)

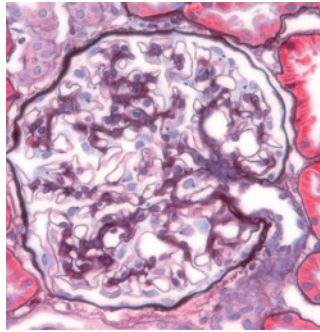
There was focal mesangial proliferation with slightly increased mesangial matrix.



HE staining (X400)

Figure 2. Light microscopic findings. (PAS staining)

Increase of mesangial matrix is not severe and it is hard to find mesangial deposition in light microscopy.



PAS staining (X400)

Figure 3. Immunofluorescence staining for C1q.

Immunofluorescence showed dominant positive staining (3+) for C1q in the glomerular mesangium.

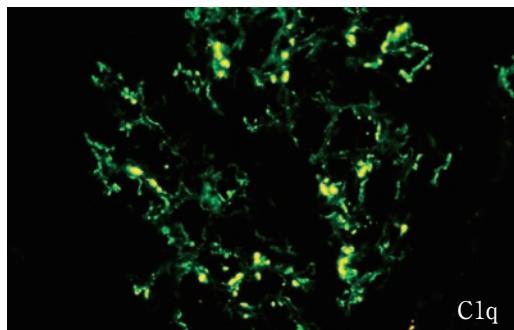
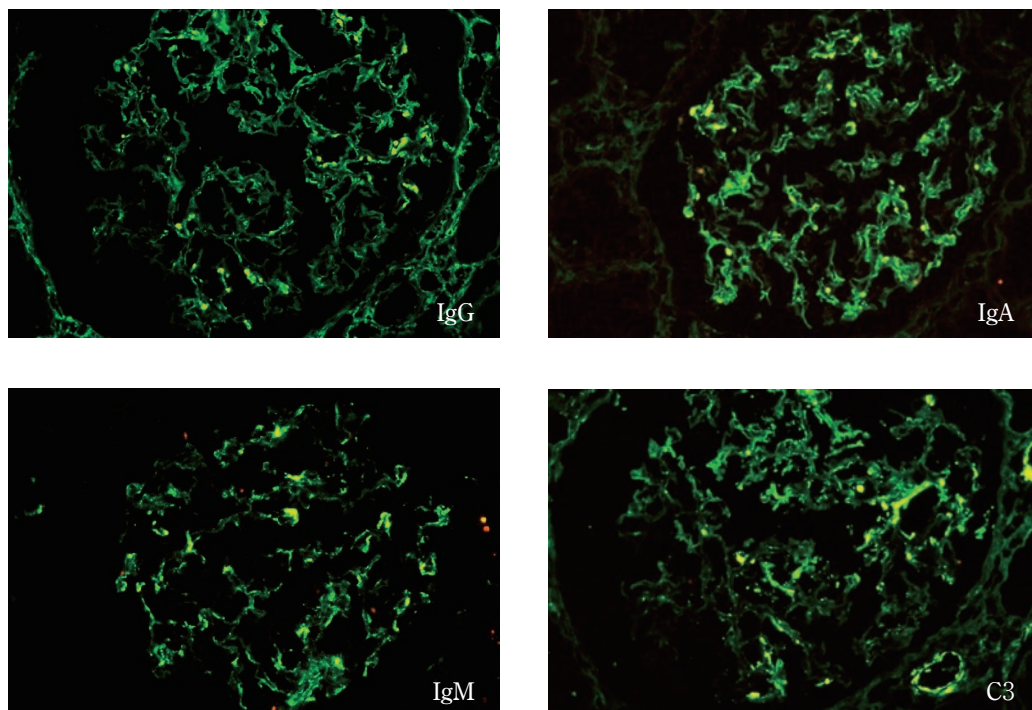
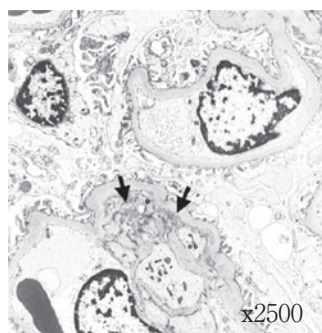


Figure 4. Immunofluorescence stainings for C3, IgA, IgG and IgM.

Immunofluorescence staining for C3 was slightly positive in the same mesangial area as C1q. Stainings for IgA, IgG and IgM were slightly positive, however, these stainings were not on mesangial lesion.

**Figure 5.** Electron microscopy findings.

Electron microscopy showed electron dense deposits in the mesangial area.

**Discussion**

Jennette and Hippi first proposed that C1q nephropathy was a distinct clinical entity that caused glomerulonephritis in the absence of SLE^{1,2}, with deposition of C1q predominantly in the mesangial area. In these early reports, C1q nephropathy had specific histopathological patterns of mainly focal or diffuse mesangial proliferative glomerulonephritis. In renal biopsies, several patterns have subsequently been

reported, ranging from minor glomerular abnormalities or mesangial proliferative glomerulonephritis to focal glomerulosclerosis³ with most recent reports describing C1q nephropathy of the focal glomerulosclerosis type. Davenport et al. and Nishida et al. reported cases of C1q nephropathy of the membranous proliferative glomerulonephritis and membranous nephropathy types^{4,5}. However, it is difficult to diagnose these cases as C1q nephropathy using only pathological findings, because positive C1q fluorescence is often seen in cases of idiopathic membranous proliferative glomerulonephritis or in membranous nephropathy itself. C1q nephropathy was originally characterized by immune deposits with dominant staining for C1q, and the entity remains controversial because of its heterogeneity. In our case, histological analysis was consistent with the presence of mesangial proliferative glomerulonephritis.

Clinically, C1q nephropathy is characterized by onset in older children and young adults with severe proteinuria or nephrotic syndrome, with resistance to steroid treatment, frequent recurrence, and a poor long-term prognosis. Asymptomatic hematuria/proteinuria is also seen in C1q nephropathy⁶ and in Japan asymptomatic hematuria/proteinuria is the predominant symptom compared to nephrotic syndrome. Thus, Japanese patients have a relatively good prognosis compared to patients in other countries. This discrepancy might be due to the widespread school health examination in Japan. In clinical studies, patients with C1q nephropathy tend to be young, with an average age of 19.6 years old⁷. Thus, our patient was slightly older than those in previous cases. The prognosis of C1q nephropathy in Japan is good, with minimal progression in many cases⁷. Since our patient had only microhematuria and no other symptoms, he did not require treatment with prednisolone or cyclosporine, and only follow-up was performed.

C1q is the first component of the classical pathway of complement activation^{8,9}. The function of C1q in the complement cascade is to attach to the Fc portion of IgM and some IgG subtypes after they have bound antigen, thereby activating the classical pathway. Together with the deposition of C1q, deposition of Ig is often detected in glomeruli in C1q nephropathy. This suggests complement activation by formation of antigen-antibody complexes in the glomeruli and is the reason that C1q nephropathy is categorized as an immune complex-type glomerulonephritis. However, the antigen involved in C1q nephropathy has not been determined. The alternative and lectin pathways are also involved in C1q nephropathy¹⁰, but the exact pathogenesis leading to mesangial C1q deposition and intense staining for C1q is unknown.

The prevalence of C1q nephropathy is 0.21-4%^{1-4,7}. However, some laboratories do not perform C1q staining in routine immunopathologic analysis of renal biopsies. For example, at Jichi Medical University, 623 patients underwent renal biopsy from 1984 to March 1994, during which time routine C1q staining for renal biopsies was not performed. Among these patients, 37 had non-IgA mesangial proliferative glomerulonephritis, including 19 who were negative for IgA and IgG staining and did not have SLE or diabetes mellitus. Some of these 19 patients may have had C1q nephropathy. Since April 1994, C1q staining has been routinely performed at Jichi Medical University. To the end of 2010, 6 cases with positive C1q staining, no IgA or IgG staining, and no SLE or diabetes were found among 3614 patients. These 6 patients may have had C1q nephropathy. The characteristics of these patients are summarized in Table 1. The prevalence of C1q nephropathy was only 0.17% at our division and low compared to previous other reports. The reason of low prevalence is that our patients are mainly composed of adults. However, we should rule out the possibility of C1q nephropathy in case of non immunoglobulin staining in renal biopsy. In our previous C1q nephropathy patients, all of 6 patients showed continuous microhematuria and proteinuria, and 2 of the 6 cases had nephrotic syndrome. Only current case shows continuous microhematu-

ria without proteinuria.

Table 1. The characteristics of patients with C1q nephropathy in our division

Case	Age	Sex	Urinary protein (g/day)	Hematuria	Pathological diagnosis	Steroid therapy	CKD stage
1	22	M	0.92	(+)	FSGS	(-)	3
2	58	F	5.23	(+)	MPGN	(+)	2
3	45	F	2.31	(+)	MesPGN with Crescent	(+)	3
4	64	M	1.84	(+)	MesPGN with Crescent	(-)	3
5	51	F	3.82	(+)	MPGN	(+)	3
6	55	M	0.91	(+)	MesPGN	(-)	2
Current case	27	M	0.08	(+)	MesPGN	(-)	1

FSGS: focal sclerotic glomerulonephritis, MPGN: membranoproliferative glomerulonephritis, MesPGN; mesangioproliferative glomerulonephritis. In all these MesPGNs, IgA and IgG deposition did not find on mesangial area.

The etiology and pathogenesis of intraglomerular deposition of C1q has not been elucidated. C1q deposition in the glomeruli may be associated with activation of classical pathway, mediated by the immune complexes, C1q affinity protein or through C1q receptor. However, there is the other possibility that C1q deposition is non-specific and related to glomerular proteinuria. Recently Vizjak et al reported the summary of 72 cases fulfilled the criteria of C1q nephropathy proposed by Janette and Hipp³. They reported that C1q nephropathy may consist of primary type and secondary type. Primary C1q nephropathy is divided into two variants, such as MCD (minimal change disease) /FSGS (focal segmental glomerular sclerosis) variant and immune-complex GN variant (mesangial PGN (proliferative glomerulonephritis) group, MN (membranous nephropathy) group, MPGN (membranoproliferative glomerulonephritis)-like group). **In their report, some patients of mesangial PGN group showed glomerular mesangial proliferative lesions, together with focal and irregular subepithelial and endothelial deposition, with persistent proteinuria and hematuria³.** Otherwise, our case has continuous microhematuria without proteinuria and the histological findings were mesangial proliferative glomerulonephritis, with only mesangial electron dense deposit. Taken together, these finding suggest C1q deposition would not be non-specific trapping that accompanies increased glomerular protein trafficking associated with proteinuria. The inflammation on mesangial area accompanying C1q deposition might produce subepithelial and endothelial deposition and be related to glomerular proteinuria. Our case may be detected in the early stage of C1q nephropathy.

However, there are some patients showing the disappearance of C1q deposits through the follow-up period¹¹. Many uncertain points remain to be solved in C1q nephropathy. The accumulation of a large number of cases in multiple centers is required for the establishment of C1q nephropathy as an independent disease entity.

References

- 1) Jennette JC, Hippi CG: Immunohistopathologic evaluation of C1q in 800 renal biopsy specimens. *Am J Clin Pathol* 83: 415-420, 1985.
- 2) Jennette JC, Hippi CG: C1q nephropathy: a distinct pathologic entity usually causing nephrotic syndrome. *Am J Kidney Dis* 6: 103-10, 1985.
- 3) Vizjak, A, Ferluga D, Rozic M, et al.: Pathology, Clinical presentations, and outcomes of C1q nephropathy. *J Am Soc Nephrol* 19: 2237-2244, 2008.
- 4) Davenport A, Maciver AG, Mackenzie JC: C1q nephropathy: do C1q deposits have any prognostic significance in the nephrotic syndrome? *Nephrol Dial Transplant* 7: 391-396, 1992.
- 5) Nishida M, Kawakatsu H, Okumura Y, et al.: C1q nephropathy with asymptomatic urine abnormalities. *Pediatr Nephrol* 20: 1669-1670, 2005.
- 6) Fukuma Y, Hisano S, Segawa Y, et al.: Clinicopathologic correlation of C1q nephropathy in children. *Am J Kidney Dis* 47: 412-418, 2006.
- 7) Hisano S, Fukuma Y, Segawa Y, et al.: Clinicopathologic correlation and outcome of C1q nephropathy. *Clin J Am Soc Nephrol* 3: 1637-1643, 2008.
- 8) Proding WM, Würzner R, Stoiber H, Dierich MP: Complement. In: *Fundamental immunology* 5th ed, ed Paul WE, Lippincott Williams Wilkins, 2003, pp1077-1103.
- 9) Berger SP, Roos A, Daha MR: Complement and the kidney: what the nephrologists needs to know in 2006? *Nephrol Dial Transplant* 20: 2613-2619, 2005.
- 10) Hisano S, Matsushita M, Fujita T, et al.: Activation of the lectin complement pathway in C1q nephropathy. *J Am Soc Nephrol* 17:256A (Abstract), 2006.
- 11) Mii A, Shimizu A, Masuda Y, et al.: Current status and issues of C1q nephropathy. *Clin Exp Nephrol* 13: 263-274, 2009.

血尿を呈した，成人発症の C1q 腎症の 1 例

菅生 太郎，斎藤 修，斎藤 孝子，秋元 哲，
井上 真，安藤 康宏，竹本 文美，草野 英二

要 約

症例は27歳男性。5年前より顕微鏡的血尿を指摘されていた。仕事で海外駐在の予定があり，赴任前に血尿の精査目的にて入院となった。経皮腎生検を行い，光顕所見ではメサンギウム増殖性糸球体腎炎の所見を認めた。蛍光抗体法にてメサンギウム領域に主として C1q の沈着を認めた。同部位に C3の僅かな沈着も認めしたが，IgA，IgG，IgM の有意な沈着は認めなかった。電顕ではメサンギウム領域に dense deposits を認めた。一方，臨床症状または採血結果からは，膠原病を疑わせる所見はなかつ

た。以上の所見より C1q 腎症と診断した。一般的に C1q 腎症では蛋白尿が主体の症状であり，場合によってはネフローゼ症候群を呈することもある。1994年4月から2010年12月までの当科での腎生検施行全3614例中，C1q 腎症と診断される患者は他に6例あったが，本症例のみが血尿単独を呈していた。本症例は C1q 腎症の発症メカニズムを考えるうえで示唆に富む症例と考えられたので，若干の考察を加えて報告する。